



Severe Recurrent Vulvovaginal Candidiasis in A Postmenopausal Diabetic Patient on Empagliflozin, An SGLT2 Inhibitor

Yogitha Sai Vempati; Jack D Sobel*

Department of Internal Medicine, Wayne State University School of Medicine, USA.

*Corresponding Author(s): Jack D Sobel

Wayne State University School of Medicine, 275 East Hancock Street, Detroit MI - 48201, USA.

Tel: 248-505-6780; Email: jsobel@med.wayne.edu

Received: Jan 30, 2023

Accepted: Mar 02, 2023

Published Online: Mar 06, 2023

Journal: Annals of Obstetrics and Gynecology

Publisher: MedDocs Publishers LLC

Online edition: <http://meddocsonline.org/>

Copyright: © Sobel JD (2023). *This Article is distributed under the terms of Creative Commons Attribution 4.0 International License*

Keywords: Sodium-glucose cotransporter-2 inhibitors; SGLT2 inhibitors; Empagliflozin; Recurrent candida vulvovaginitis; RVVC; type 2 diabetics; Genital mycotic infections; Postmenopausal vaginitis.

Abbreviations: HR: Thormone replacement therapy; RVVC: recurrent vulvovaginal candidiasis; SGLT2i: sodium glucose cotransporter 2 inhibitors; T2DM: type 2 diabetes mellitus; T2D: type 2 diabetics; VVC: vulvovaginal candidiasis

Introduction

Recurrent VVC is defined as three or more episodes of vulvovaginal candidiasis (VVC) within a year but may also manifest as chronic persistent vulvovaginitis [1]. Risk factors for precipitating VVC are antibiotic use, high estrogen-containing oral contraceptives, pregnancy, sexual activity, and uncontrolled diabetes mellitus [2]. Most cases of RVVC occur in premenopausal women and, when occurring after menopause, exogenous triggers

including drugs are usually identified. In this population, genital mycotic infections are common in patients with poorly controlled diabetics [3]. Sodium-glucose cotransporter-2 inhibitors (SGLT2i), a new class of oral antidiabetic agents, act through an insulin-independent mechanism by inhibiting glucose reabsorption in proximal tubules of the kidneys, increasing urinary glucose excretion, and reducing circulating glucose.

Abstract

Vulvovaginal Candidiasis (VVC) is less common in postmenopausal women because of fungal estrogen dependence. Postmenopausal women with underlying risk factors for VVC, such as hormone replacement therapy, uncontrolled diabetes mellitus, and immunosuppression caused by medication or disease, are at risk for chronic or recurrent VVC. The Sodium-Glucose Cotransporter-2 (SGLT2) inhibitor class has been associated with an increased risk of Genital Mycotic Infections (GMI) and urinary tract infections, likely the consequence of drug-induced glycosuria. Although cases have been reported describing vulvovaginal candidiasis in Type 2 Diabetics (T2D) following SGLT2 inhibitors, this is the first such report accompanying the use of Empagliflozin. We report a 69-year-old female with Type 2 Diabetes Mellitus (T2DM) who developed severe and recurrent vulvovaginal candidiasis while her diabetes is well controlled utilizing the recently released SGLT2 inhibitor empagliflozin. Despite existing reports in the literature indicating the association of vulvovaginal candidiasis with this drug class, gynecologist physicians remained largely unaware of this complication in postmenopausal women and are prescribed SGLT2 inhibitors without warning and monitoring and frequently marked delay in diagnosis.



Cite this article: Sai Vempati Y, Sobel JD. Severe Recurrent Vulvovaginal Candidiasis in A Postmenopausal Diabetic Patient on Empagliflozin, An SGLT2 Inhibitor. *Ann Obstet Gynecol.* 2023; 6(1): 1046.

SGLT2 inhibitors are frequently recommended as an addition in dual or triple pharmacotherapy when metformin alone fails to achieve normoglycemia. Additional benefits include promoting weight loss, posing a low risk of hypoglycemia, lowering systolic blood pressure, and reducing cardiovascular and renal events in high-risk patients [4]. SGLT2i by inducing pharmacological glycosuria increases the risk of urinary tract infections and mycotic genital infections [4,5]. The risk of genital infections is five times more likely than other antidiabetic agents [5]. We present the case of a 69-year-old female with type 2 diabetes mellitus (T2DM) who developed recurrent VVC while on empagliflozin, a recently introduced SGLT2 inhibitor.

Case Presentation

A 69-year-old woman with T2DM was referred to our Vaginitis Clinic in April 2022 because of uncontrolled vulvar itching and vulvovaginal burning sensation over the previous 5 months. She had been prescribed vulvar topical betamethasone cream that reduced her itching, but recurred following steroid cessation. Her medical history was significant for hyperlipidemia, hypothyroidism, and asthma. She has been prescribed Januvia (Sitagliptin), empagliflozin and repaglinide for diabetes, Pravastatin 40mg, and Levothyroxine 50 mcg. She has not been on any Hormone Replacement Therapy (HRT) for several years. Her hemoglobin A1c at the time of presentation was 7.2% and her BMI (Body Mass Index) was 30. Due to persistent symptoms and chronic extensive undiagnosed rash, a vulvar biopsy performed showed nonspecific chronic inflammatory changes. No histologic studies for fungal presence were obtained. Physical examination at presentation in our clinic revealed an extensive patchy erythematous vulvar rash extending to the bilateral inguinal folds and perineal area, thickened sub-clitoris, labial swelling, vestibular erythema, and diffuse vaginal thinning noted (Fig.1). Fungal vulvovaginitis was suspected clinically, with positive wet mount microscopy and *Candida albicans* was confirmed on yeast cultures. She was prescribed topical application of nystatin 100,000 units/g and triamcinolone 0.1% ointment twice a day and 3 doses of 150mg fluconazole at 72-hour intervals followed by 150mg fluconazole once weekly maintenance therapy. She rapidly responded with complete resolution of symptoms and signs (Fig 2), however she decided to stop the antifungal medication. Symptoms recurred after 3 weeks of maintenance therapy having continued empagliflozin therapy against our advice. Restarted oral 150mg fluconazole induction and maintenance therapy with recommendations to discontinue the SGLT2 inhibitor and at follow-up off empagliflozin she remained completely asymptomatic and yeast culture negative.

Discussion

Prevalence of VVC in postmenopausal women remains understudied but is reportedly low in non-HRT users, ranging from 3% to 7% [6,7]. When VVC presents in postmenopausal women it is frequently missed and not considered, especially in those with no prior history of VVC. Post-menopausal patients are still susceptible to being colonized by fungal organisms despite being estrogen deprived [8]. When VVC does occur in postmenopausal women, likely contributory factors are hormone replacement therapy, unrecognized and uncontrolled diabetes mellitus, and the use of topical steroids. Added to this list in post-menopausal diabetics are the entire class of SGLT2 inhibitors [9,10]. We report a case of severe vulvovaginal candidiasis in a postmenopausal woman who has been on empagliflozin. RVVC was managed with induction and maintenance fluconazole therapy and discontinuation of empagliflozin. There is a

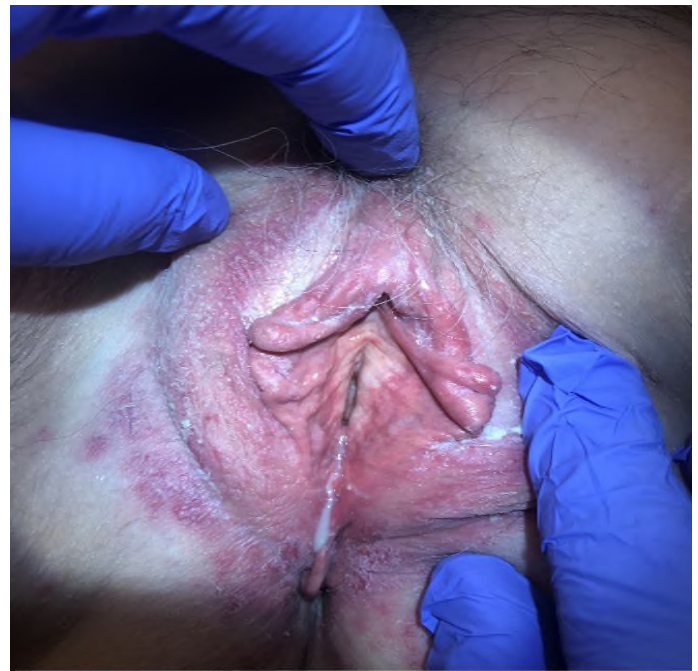

Figure 1: Before treatment. Vulvovaginal candidiasis showing extensive patchy erythematous rash extending to bilateral inguinal folds with subclitoral thickening, labial swelling, and diffuse vestibular erythema.

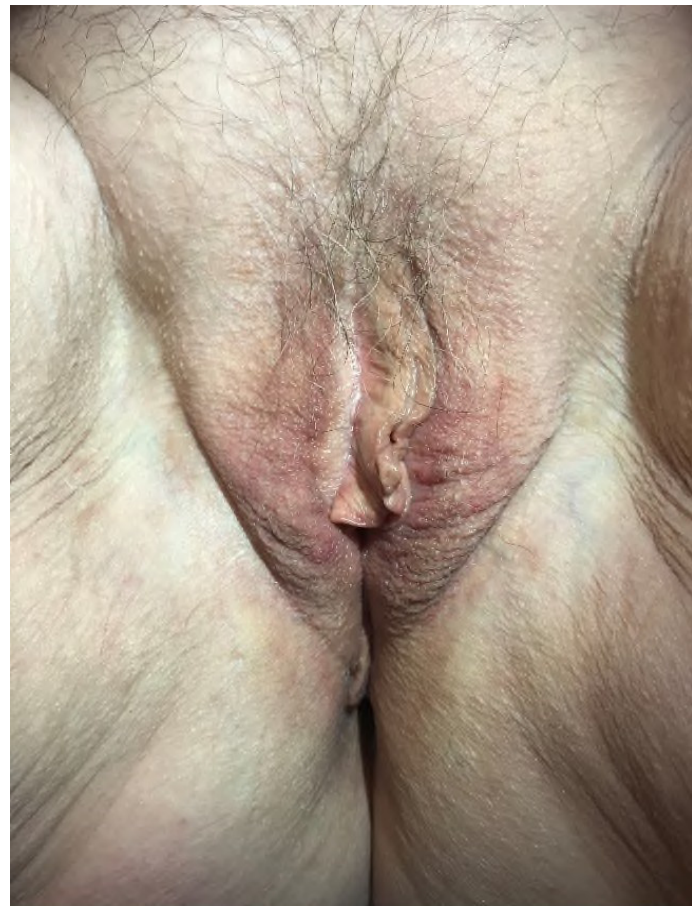


Figure 2: After treatment. Complete resolution of vulvar rash.

lack of awareness among gynecologists and general practitioners as to the causation of VVC in post-menopausal women and there are now frequent reports indicating that all SGLT2 inhibitors cause this syndrome. Strong consideration should be given to avoiding SGLT2 inhibitors in women with RVVC in the absence of prophylactic antifungal therapy.

Data Availability

Data supporting the report's conclusion are included within the manuscript.

Consent

Signed written consent from the patient was obtained.

Conflicts of interest

The authors declared that they have no conflict of interest.

Funding

There are no sources of funding.

References

1. Denning DW, Kneale M, Sobel JD, Rautemaa-Richardson R. Global burden of recurrent vulvovaginal candidiasis: A systematic review. *Lancet Infect Dis.* 2018; 18: e339-e347.
2. Sobel JD, Faro S, Force RW, Foxman B, Ledger WJ, et al. Vulvovaginal candidiasis: Epidemiologic, diagnostic, and therapeutic considerations. *Am J Obstet Gynecol.* 1998; 178: 203-211.
3. Nyirjesy P, Sobel JD. Genital mycotic infections in patients with diabetes. *Postgrad Med.* 2013; 125: 33-46.
4. Shanti Pittampalli, Satya Upadhyayula, Hema Madhuri Mekala. Risks vs Benefits for SGLT2 Inhibitor Medications. *Fed Pract.* 2018; 35: 45-48.
5. Rizzi M, Trevisan R. Genitourinary infections in diabetic patients in the new era of diabetes therapy with sodium-glucose cotransporter-2 inhibitors. *Nutr Metab Cardiovasc Dis.* 2016; 26: 963-970.
6. Fischer G, Bradford J. Vulvovaginal candidiasis in postmenopausal women: the role of hormone replacement therapy. *Journal of Lower Genital Tract Disease.* 2011; 15: 263-267.
7. Ross CA. Post-menopausal vaginitis. *Journal of Medical Microbiology.* 1978; 11: 209-214.
8. Sobel JD, Chaim W, Leaman D. Recurrent vulvovaginal candidiasis associated with long-term tamoxifen treatment in postmenopausal women. *Obstetrics & Gynecology.* 1996; 88: 704-706.
9. Kristina M Johnsson, Agata Ptaszynska, Bridget Schmitz, Sugg J, Parikh SJ, et al. Vulvovaginitis and balanitis in patients with diabetes treated with dapagliflozin. *Journal of Diabetes and its complications.* 2013; 27: 479-484.
10. Nyirjesy P, Sobel JD, Fung A, Mayer C, Capuano G, et al. Genital mycotic infections with canagliflozin, a sodium glucose cotransporter 2 inhibitor, in patients with type 2 diabetes mellitus: a pooled analysis of clinical studies. *Current Medical Research and Opinion.* 2014; 30: 1109-1119.